

# High-Performance Motion Correction of Fetal MRI

B. Kainz<sup>1,2</sup>, D. F. A. Lloyd<sup>2</sup>, A. Alansary<sup>1</sup>, M. Kuklisova Murgasova<sup>2</sup>, R. Khlebnikov<sup>2</sup>,  
D. Rueckert<sup>1</sup>, M. Rutherford<sup>2</sup>, R. Razavi<sup>2</sup>, and J.V. Hajnal<sup>2</sup>

<sup>1</sup>Department of Computing, Imperial College London, UK

<sup>2</sup>Division of Imaging Sciences & Biomedical Engineering, King's College London, UK

## Abstract

*Fetal Magnetic Resonance Imaging (MRI) shows promising results for pre-natal diagnostics. The detection of potentially life-threatening abnormalities in the fetus can be difficult with ultrasound alone. MRI is one of the few safe alternative imaging modalities in pregnancy. However, to date it has been limited by unpredictable fetal and maternal motion during acquisition. Motion between the acquisitions of individual slices of a 3D volume results in spatial inconsistencies that can be resolved by slice-to-volume reconstruction (SVR) methods to provide high quality 3D image data. Existing algorithms to solve this problem have evolved from very slow implementations targeting a single organ to general high-performance solutions to reconstruct the whole uterus. In this paper we give a brief overview over the current state-of-the-art in fetal motion compensation methods and show currently emerging clinical applications of these techniques.*

Categories and Subject Descriptors (according to ACM CCS): I.3.8 [Computer Graphics]: Applications—I.4.3 [Image Processing And Computer Vision]: Enhancement—Registration

## 1. Introduction

Evaluation of fetal organs and the placenta is an important diagnostic tool during prenatal screening and is considered to be an indicator for fetal health after birth. Fetal Magnetic Resonance Imaging (MRI) allows to acquire high resolution slices from the fetus at a large field of view and with good tissue contrast [Lev04]. However, the fetus is not sedated during these scans and may move freely inside the uterus. Because of a scan time of up to 500 ms per slice, motion artefacts are likely to corrupt volumetric scans. Therefore, several (usually 3–12) orthogonal and oblique stacks of slices are acquired and reconstructed using approaches based on slice-to-volume registration (SVR) to obtain an artefact free, high resolution volume of a fetal target region [KMQR\*12, KSW\*15, RGI\*06]. This process is often applied only to small regions and organs with rigid body characteristic such as the fetal brain. Usually, these areas have to be identified by manual labour intensive segmentation methods. Such approaches cannot be applied to the whole fetal body and uterus because of the assumption of rigid motion in the 2D to 3D registration step of SVR methods. Different areas in each slice that are likely to move in different directions will break this assumption. Because an extension of 2D-3D registration to non-rigid deformations is not well-constrained, current SVR approaches will fail for non-rigid deformations and unpredictable organ shapes. Patch-to-Volume registration (PVR) uses flexible subdivision of the input space into overlapping and partly rigid image patches [KAM\*15]. This way the motion compensation and manual segmentation problem for large field of views in stacks of 2D slices is partly solved. PVR relies on the fact that certain sub-

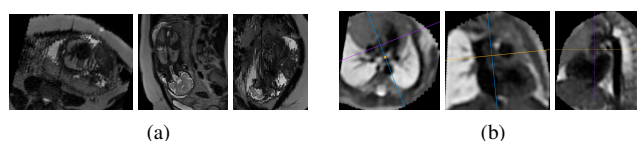


Figure 1: Multi-planar reconstruction of a multi-slice single-shot fast spin echo (ssFSE) MRI stack in a normal fetus (a). The reconstructed planes orthogonal to the acquisition plane show the extent of fetal movement between slices. Following the application of PVR to multiple overlapping stacks of 2D images, a fully navigable 3D volume of the fetal thorax shows clinically relevant cutting planes (b), providing detailed views of the extracardiac vasculature.

regions of a scanned anatomy are almost rigid so that they can be reconstructed using rigid assumptions for 2D/3D registration. Robust statistics is used to identify mis-registered, redundant or heavily corrupted data [KMQR\*12, RGI\*06]. Data consistency is reached by oversampling a region of interest with different scan orientations. We increase the granularity of the input data by using 2D data patches of arbitrary shape instead of whole slices for SVR reconstruction. That way, multiple, large motion corrupted field of views can be reconstructed and regions with rigid motion can be found automatically and patch sizes can be hierarchically increased to achieve optimal contextual information for the required 2D/3D registration. Acceleration using graphics processing units (GPUs) is used to provide results within reasonable time.

## 2. Current Use and Validation in the Clinical Practice

While GPU accelerated SVR has become a standard method for the examination of the fetal brain [FMA\*14, SMM\*15], the clinical application of PVR to other parts of the fetal body is currently under investigation. For example the antenatal diagnosis of important vascular abnormalities allows for both better informed parental counselling and the planned provision of potentially life-saving care after birth. The fetal vasculature can however be difficult to visualise with ultrasound [Sim09] and the prenatal diagnosis of conditions such as coarctation of the aorta may be based solely on subtle anatomical markers, which may be difficult to detect before birth [JAS\*12]. PVR is currently applied to antenatally acquired MRI data from fetuses with and without congenital heart disease and validated using examination of standard planes with ultrasound as shown in Figures 2(a) and 2(b). PVR makes it possible to generate highly detailed models of the fetal cardiac vascularity, Figure 2(c). For educational purposes and for potential planning of post-natal intervention we use photo-realistic volume rendering [KPB12], Figure 2(d).

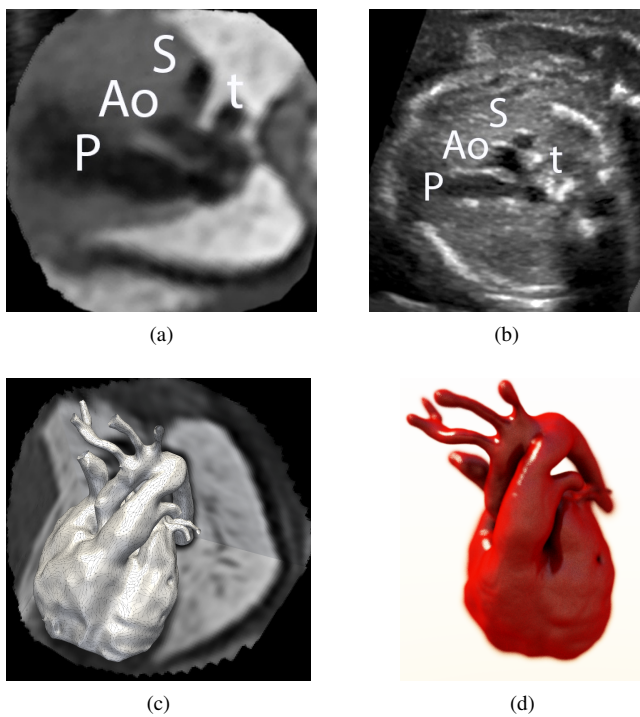


Figure 2: Validation of a motion compensated volume (a) with a standard fetal “three vessel view” from ultrasound (b). P = pulmonary artery, Ao = aorta, S = superior caval vein, t = trachea. PVR allows to generate highly accurate 3D models (c) [LKvA\*16, WVV\*05], which can be rendered photorealistically [KPB12] for educational and intervention planning purposes.

## 3. Future Directions

PVR enables reconstructing the clinically relevant parts of the fetus and highly variable organs like for example the placenta. This organ is one of the most complicated organs to examine because of its unpredictable shape, orientation, and location. Usually the placenta is

only examined after birth, on a flat surface. The lack of comparable pre-natal representations of the placenta’s structures makes a clinical examination more difficult. To provide an intuitive pre-natal view into this vital organ we are currently evaluating an extension of our image processing pipelines based on a novel application of shape abstraction. We propose to use a flexible cutting plane, which is supported by a mean-curvature flow skeleton [TAOZ12] generated from the triangulated polygonal mesh of an automatic placenta segmentation. This curved cutting plane can be textured using techniques similar to Curved Planar Reformation [KFW\*02]. Figure 3 shows an overview of our current placenta segmentation and reconstruction framework for visualization. Personal communication with our clinical partners revealed that such a representation is desirable since it compares well to a flattened placenta after birth. However, evaluation, verification and the definition of an examination standard are yet to be completed.

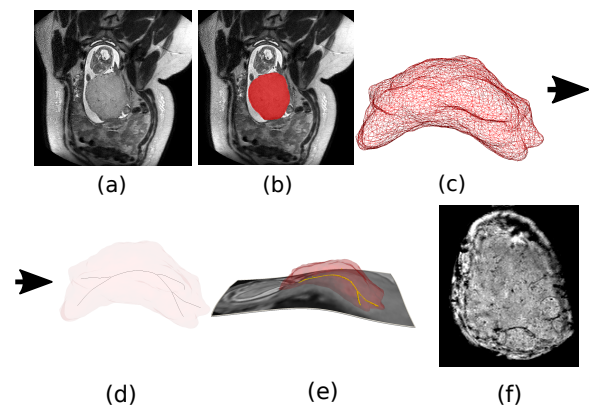


Figure 3: An overview of our placenta visualization approach. A native plane (a) cannot represent all structures of the placenta at once. Therefore, we use our segmentation method (b), correct the motion in this area using [KAM\*15], project the placenta mask into the the resulting isotropy resolved volume (c), extract the mean curvature flow skeleton [TAOZ12] (black lines in (d)), use the resulting points to support a curved surface plane (e) and visualize this plane with curved planar reformation [KFW\*02] (f). The plane in (f) covers only relevant areas, hence gray value mapping can be adjusted automatically to emphasize placental structures.

## 4. Conclusions

Motion compensation techniques like GPU accelerated SVR and PVR have revolutionised the examination of fetal MRI. Fully navigable high resolution 3D volumes are essential for clinical diagnostics and advanced visualization. Currently, we validate the clinical correctness of our methods by comparing it to standard views from ultrasound imaging at a gestational age between 20 – 39 weeks. Fully automatic scan evaluation makes our methods highly reproducible and reliable. The integration of advanced GPU programming techniques allowed us to peruse computational avenues, which would have been unthinkable a few years ago and to reach close to real-time performance for many parts of our image processing pipelines. Fetal MRI has reached the state, where novel reproducible and verified visualization paradigms can have a significant impact on efficient clinical examination and decision-making.

## References

- [FMA\*14] FERRAZZI G., MURGASOVA M. K., ARICHI T., MALAMATENIOU C., FOX M. J., MAKROPOULOS A., ALLSOP J., RUTHERFORD M., MALIK S., ALJABAR P., HAJNAL J. V.: Resting State fMRI in the moving fetus: A robust framework for motion, bias field and spin history correction. *NeuroImage* 101 (2014), 555 – 568. 2
- [JAS\*12] JOWETT V., APARICIO P., SANTHAKUMARAN S., SEALE A., JICINSKA H., GARDINER H.: Sonographic predictors of surgery in fetal coarctation of the aorta. *Ultrasound Obstet Gynecol* 40 (2012), 47–54. 2
- [KAM\*15] KAINZ B., ALANSARY A., MALAMATENIOU C., KERAUDREN K., RUTHERFORD M., HAJNAL J. V., RUECKERT D.: Flexible reconstruction and correction of unpredictable motion from stacks of 2D images. In *Medical Image Computing and Computer-Assisted Intervention–MICCAI*. Springer LNCS 9350, 2015, pp. 555–562. 1, 2
- [KFW\*02] KANITSAR A., FLEISCHMANN D., WEGENKITTL R., FELKEL P., GROLLER E.: CPR – Curved Planar Reformation. In *Proc. IEEE VIS 2002* (Nov 2002), pp. 37–44. 2
- [KMQR\*12] KUKLISOVA-MURGASOVA M., QUAGHEBEUR G., RUTHERFORD M. A., HAJNAL J. V., SCHNABEL J. A.: Reconstruction of Fetal Brain MRI with Intensity Matching and Complete Outlier Removal. *Medical Image Analysis* 16, 8 (2012), 1550–60. 1
- [KPB12] KROES T., POST F. H., BOTHA C. P.: Exposure render: An interactive photo-realistic volume rendering framework. *PLoS ONE* 7, 7 (July 2012), e38586. 00012. 2
- [KSW\*15] KAINZ B., STEINBERGER M., WEIN W., MURGASOVA M., MALAMATENIOU C., KERAUDREN K., TORSNEY-WEIR T., K., ALJABAR P., RUTHERFORD M., HAJNAL J., RUECKERT D.: Fast Volume Reconstruction from Motion Corrupted Stacks of 2D Slices. *IEEE Trans Med Imaging* 34, 9 (2015), 1901–1913. 1
- [Lev04] LEVINE D.: Fetal Magnetic Resonance Imaging. *J Matern Fetal Neonatal Med* 15, 2 (Feb. 2004), 85–94. 1
- [LKvA\*16] LLOYD D. F. A., KAINZ B., VAN AMEROM J. F. P., PUSHPARAJAH K., SIMPSON J. M., ZIDERE V., MILLER O., SHARLAND G., ZHANG T., LOHEZIC M., ALLSOP J., FOX M., MALAMATENIOU C., RUTHERFORD M., HAJNAL J., RAZAVI R.: Three-Dimensional Modelling of the Fetal Vasculature from Prenatal MRI using Motion-Corrected Slice-to-Volume Registration. In *International Society for Magnetic Resonance in Medicine Meeting, 07–13 May, Singapore* (2016). 2
- [RGI\*06] ROUSSEAU F., GLENN O. A., IORDANOVA B., RODRIGUEZ-CARRANZA C., VIGNERON D. B., BARKOVICH J. A., STUDHOLME C.: Registration-Based Approach for Reconstruction of High-Resolution In Utero Fetal MR Brain Images. *Academic Radiology* 13, 9 (2006), 1072 – 1081. 1
- [Sim09] SIMPSON J.: Impact of fetal echocardiography. *Ann Pediatr Cardiol* 2, 1 (2009), 41–50. 2
- [SMM\*15] SCHUH A., MURGASOVA M., MAKROPOULOS A., LEDIG C., COUNSELL S. J., HAJNAL J. V., ALJABAR P., RUECKERT D.: *Spatio-temporal Image Analysis for Longitudinal and Time-Series Image Data: Third International Workshop, STIA 2014, Held in Conjunction with MICCAI 2014, Boston, MA, USA, September 18, 2014, Revised Selected Papers*. Springer International Publishing, 2015, ch. Construction of a 4D Brain Atlas and Growth Model Using Diffeomorphic Registration, pp. 27–37. 2
- [TAOZ12] TAGLIASACCHI A., ALHASHIM I., OLSON M., ZHANG H.: Mean curvature skeletons. *Computer Graphics Forum* 31, 5 (2012), 1735–1744. 2
- [WWV\*05] WOLF I., VETTER M., WEGNER I., BÖTTGER T., NOLDEN M., SCHÖBINGER M., HASTENTEUFEL M., KUNERT T., MEINZE H.-P.: The Medical Imaging Interaction Toolkit. *Medical Image Analysis* 9, 6 (2005), 594 – 604. 2